



■ Case Report

Calcified Abdominal Pregnancy with 17 Years of Evolution: A Case Report

Mandefro Yilma,¹ Biresaw Wassihun²

¹College of Medicine and Health Sciences, Hawassa University, Hawassa, Ethiopia

²College of Medicine and Health Sciences, Arba Minch University, Arba Minch, Ethiopia

ABSTRACT

Background: Calcified abdominal pregnancy (lithopedion) is a rare phenomenon and there are less than 300 cases reported in the medical literature. We report here a rare case of long-standing abdominal pregnancy diagnosed computerized tomography. **Case presentation:** In this case, a 42 year-old Ethiopian woman presented to the outpatient department of Mekane Selam Hospital with intermittent longstanding abdominal pain that is worsened over the last 2 weeks. She had her only pregnancy 17 years earlier. She came to our hospital with pain and a tumoral mass of approximately 20 centimeters in diameter. Complementary examinations (abdominal X-ray, ultrasonography, and computerized tomography) was done. The final assessment was abdominal pregnancy with calcification (lithopedion) and she was counseled about the condition and management. Surgical intervention was decided but she refused the operation due to fearing surgical complications. **Conclusion:** Abdominal pregnancy a serious condition with significant maternal and perinatal mortality. The diagnosis of the disease was missing during antenatal care. Good history taking and physical examination are very important in this case, and also the imaging studies is vital. Due to the absence of adequate medical attention for clinicians and health workers, we suggest that the clinicians should be alert in diagnosis of this disease.

Keywords: abdominal pregnancy, lithopedion

Corresponding Author

Biresaw Wassihun,
College of Med. and Health Sciences,
Arba Minch University, Arba Minch,
Ethiopia. Bireswas@gmail.com

Introduction

Abdominal pregnancy is a variant of ectopic pregnancy and the placenta is often attached to multiple sites such as liver, omentum, bowel, and cul-de-sac.¹⁻⁵ It is rare condition that occurs

1:11,000 pregnancies and 1:100 ectopic gestations.^{3,6} Abdominal pregnancy has high morbidity and mortality for both the mother and fetus (0-20%) and (40-95%) respectively.¹

Maternal morbidity and mortality can be

reduced if diagnosed and treated early.^{1,6} If the abdominal pregnancy remains undetected and untreated and if fetal demise occurs, lithopedion formation, that is calcification of fetal parts and surrounding membranes is an expected outcome.^{2,3,7} Lithopedion occurs in 1.5-1.8% of abdominal pregnancies.^{1,2,6,8} There have been fewer than 300 cases in 400 years of world medical literature.^{3,6,7} Nowadays it is unusual for a dead fetus to remain in the abdomen for a long period, mostly detected on imaging done for other reasons. The duration of retention of the dead fetus varies between 4 and 70 years while the patients' age ranges from 20 to 100 years.^{2,4} We report a case of abdominal pregnancy confirmed by computerized tomography(CT-scan).

Case presentation

A 42years old Ethiopian woman presented to the outpatient department of Mekane Selam Hospital with intermittent longstanding abdominal pain that gets worsened over the last 2weeks. She had a history of signs and symptoms of pregnancy before 17 years which lasts for about 8months and then disappeared by itself. She didn't expel any product of conceptus. She was not booked for antenatal care. She had also a history of failure to conceive despite unprotected sexual intercourse right after this incident and for this reason, she divorced 10years back. Her menses were regular and stopped a year back. She had a history of repeated malaria attacks. She had a urinary complaint like the frequency of urination. She has no vaginal bleeding and discharge, no pulmonary complaint, and no bowel habit change. For the above complaint, she visited the local health center and treated for PID but there was no improvement. She

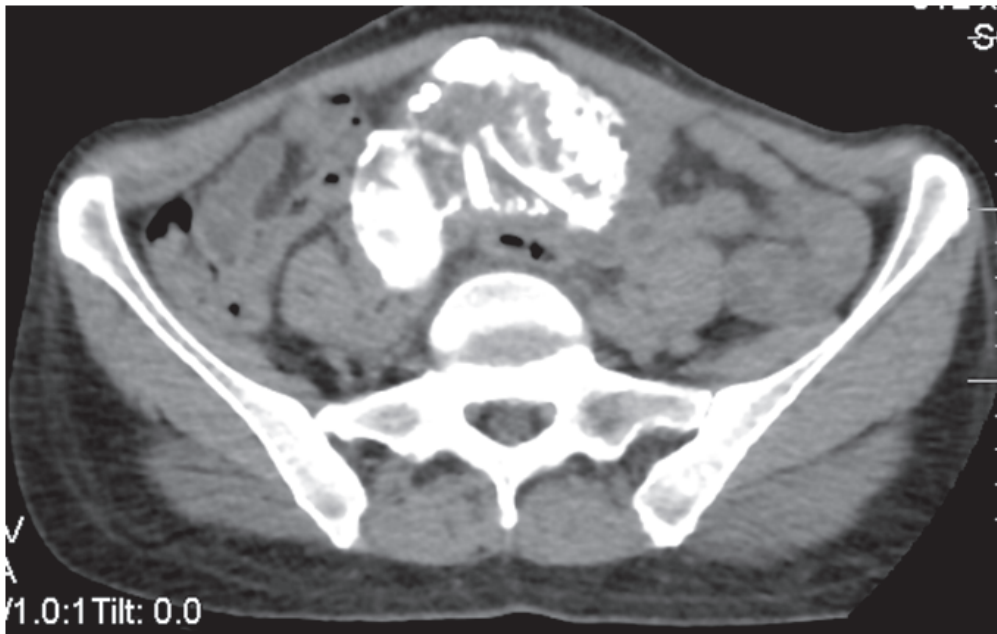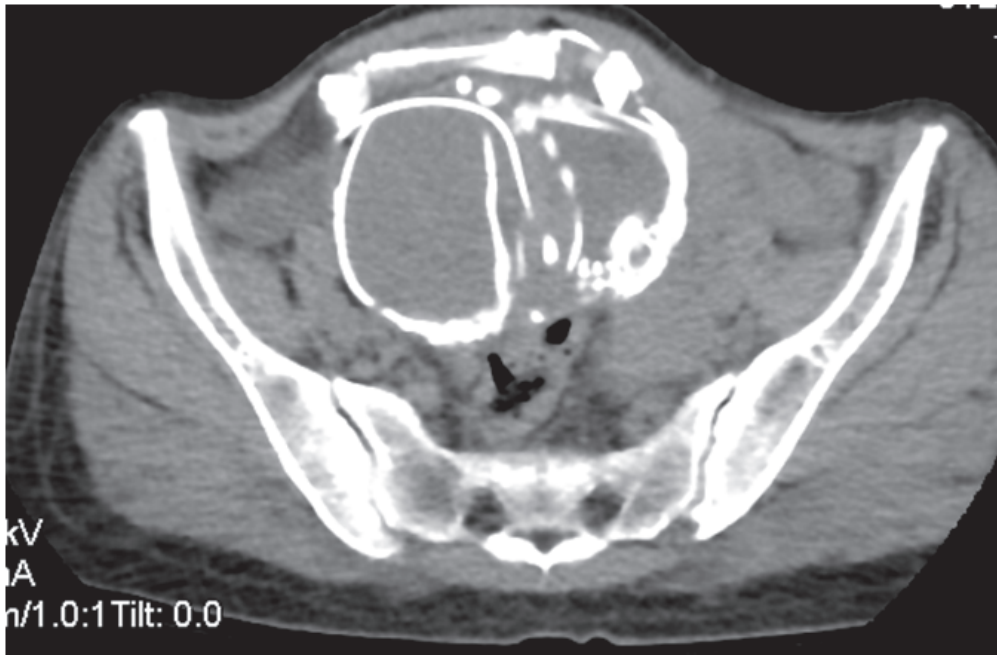
was finally referred to our hospital for better evaluation and treatment.

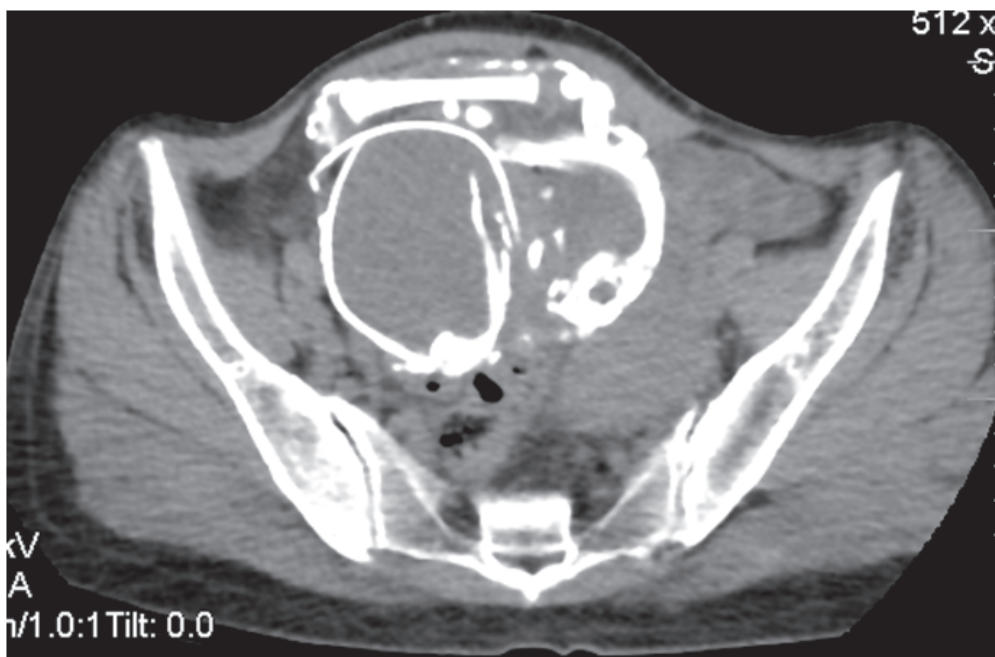Physical examination revealed chronic sick looking. The blood pressure was 100/70 mmHg and the pulse rate was 94 beats per minute. The temperature was 36.1^oC. The conjunctiva was pink and non-icteric sclera. The thyroid gland was enlarged by 2x4cm. The chest was clear and resonant and heart sounds were normal. There were 20 weeks sized stony hard abdomino pelvic mass which was mobile with minimal tenderness, more on the right side.

It moves along with the cervix during the bimanual examination. The spleen was enlarged around 6cm below the left costal margin. The cervix was smooth and pushed posteriorly.

The hemoglobin level was 15.9 g/dl, WBC 2.8 x10⁹/L, and the platelet count was 160x 10⁹/L. The ESR was 15 mm/hr. The liver, renal, and thyroid function tests all were within a normal range. The ultrasound showed an empty uterus, there is 12 x 18 cm calcified mass on the right side of the uterus, which is difficult to delineate it from the uterus. The spleen was 14 cm enlarged.

The CT-Scan showed a fetus in the right lower abdomen with some compression and distorted fetal bony parts, pushing the uterus and urinary bladder to the left side. There was a segment of the sigmoid colon adjacent to the fetus which shows focal dilatation with air. The final assessment was abdominal pregnancy with calcification (lithopedion) and she was counseled about the condition and management. Surgical intervention was decided but she refused the operation due to fearing surgical complications and she went against medical advice.





Discussion

Abdominal pregnancy mostly results from the rupture of tubal or ovarian pregnancy into the abdominal cavity with implantation.^{1,3} It is associated with high maternal and perinatal morbidity and mortality.⁵ The fetal and maternal prognosis depends on bloody supply and intra-abdominal hemorrhages and sepsis in mother respectively. The successful fetal outcome may be seen if the placenta gets implanted into a highly vascular organ.³ Abdominal pregnancy has a complex course and sometimes undergo calcification instead of being absorbed.⁴ The prerequisites for the development of lithopedion are extrauterine pregnancy, fetal death after 3 months of pregnancy, the egg must be sterile, failure of detection and presence of suitable conditions for calcium deposition.^{1,2,3}

The age of patients at diagnosis varied from 20 to 100 years. The period of fetal retention ranged from 4-60 years.^{2,4,9} In our case, the age is 42 years and the period of retention is unknown, but it is reasonable to presume that it would be at least 17 years.

Although symptoms such as pelvic pain, weight sensation in the abdomen, urinary bladder, and bowel symptoms may occur, most cases remain asymptomatic for years and discovered incidentally on imaging and surgery.^{2,4,8} Rare complications such as bladder and rectum perforation, extrusion of fetal parts through the abdominal wall, rectum, and vagina, and intestinal perforation have been reported.^{2,5} The diagnosis is made by a suggestive clinical history, abdomino-pelvic mass found during examination and imaging.^{1,2,3,8} In our case, the diagnosis was confirmed by computerized tomography (CT).

Infertility was due to the distortion of pelvic anatomy hindering ovum pickup caused by lithopedion. Removal of the lithopedion restored the Tubo-ovarian relationship resulting in conception within 2 months of surgical intervention.⁹ The long-standing history of infertility for our case may be from fallopian tube blockade result from adhesion of the tube with surrounding structures and or distortion of Tubo-ovarian relationship by the mass.

The mortality from abdominal pregnancy is 7.7

times greater than a tubal pregnancy and 90 times higher than from intrauterine pregnancy.¹⁰ Therefore, adequate preoperative preparations including compatible blood and blood products and a multidisciplinary approach should be made.

Conclusions

Abdominal pregnancy is a rare and serious condition with significant maternal and perinatal mortality. Early detection and management

decrease maternal morbidity and mortality. We recommend the clinicians document site of pregnancy as soon as a missed period.

Conflicts of Interest

The authors declare no conflicts of interest

Sources of funding

Not declared

References

1. Mohamed NA, Hajji IA, Omar SA, Kalib KS, Ali AH. Calcified Abdominal Pregnancy with Five Years of Evolution (Lithopedion): A Case Report. *Open Journal of Obstetrics and Gynecology*. 2016 Jun 23;6(8):515-9.
2. Passini Júnior R, Knobel R, Parpinelli MÂ, Pereira BG, Amaral E, Surita FG, Lett CR. Calcified abdominal pregnancy with eighteen years of evolution: case report. *Sao Paulo Medical Journal*. 2000 Nov;118(6):192-4.
3. Mitra KR, Ratnaparkhi R, Gedam BS, Tayade KA. An unusual case of retained abdominal pregnancy for 36 years in a postmenopausal woman. *International Journal of Applied and Basic Medical Research*. 2015 Sep;5(3):208.
4. Ramos-Andrade D, Ruivo C, Portilha MA, Brito JB, Caseiro-Alves F, Curvo-Semedo L. An unusual cause of intra-abdominal calcification: A lithopedion. *European journal of radiology open*. 2014 Jan 1;1:60-3.
5. Daniel N, Bashir B, Ibrahim A, Swati S. A 26-Year-Old Retained Demised Abdominal Pregnancy Presenting with Umbilical Fistula. *Case reports in obstetrics and gynecology*. 2014;2014.
6. Rahman MM, Quddush AR, Islam M, Sen S, Jahan A, Begum F, Boursleea RA, Rayen J. Calcified abdominal pregnancy with eight years of evolution. *Community-Based Medical Journal*. 2012;1(1):33-4.
7. Irick MB, Kitsos CN, O'Leary JA. Therapeutic aspects in the management of a lithopedion. *The American surgeon*. 1970 Apr;36(4):232-4.
8. Jain T, Eckert LO. Abdominal pregnancy with lithopedion formation presenting as a pelvic abscess. *Obstetrics & Gynecology*. 2000 Nov 1;96(5):808-10.
9. Medhi R, Nath B, Mallick MP. Lithopedion diagnosed during infertility workup: a case report. *SpringerPlus*. 2014 Dec 1;3(1):151.
10. J. N. Martin, J. K. Sessums, and R. W. Martin, "Abdominal pregnancy: current concepts of management," *Obstetrics and Gynecology*, vol. 71, no. 4, pp. 549-557, 1988