



Case Report

Rare Manifestation of a Sigmoid Tumour: Ovarian Metastasis of Sigmoid Adenocarcinoma

Benlghazi A, Belouad M, Vassine B, Saad B, Ait BR, Elmagoub F,
Hassani MLY, Baba H, MLY A, Kouach J

Department of Gynecology-obstetrics, Military Hospital of Instruction
Mohammed V, Rabat, Morocco.

ABSTRACT

Colon cancer is the most frequently occurring colorectal cancer. The presenting signs are mainly related to transit disorders, rectal bleeding and abdominal pain. Colon cancer occasionally can be discovered after complications like intestinal obstruction or perforation. Synchronous metastases, although common at diagnosis (25% of patients), are an exceptional way to detect this cancer. We present a case of an isolated synchronous metastasis to the ovary mistaken for a primary ovarian cancer arising from a previously asymptomatic tumor of the colon.

Corresponding author:

Benlghazi abdelhamid:
Department of Gynecology-
Obstetrics, Military Hospital of
Instruction Mohammed V,
Rabat, Morocco.
benlghaziabdelhamid333@gmail
.com
Telephone number:
+212657963722

Keywords : Krukenberg Tumour, Synchronous Ovarian Metastases,
Prognosis

INTRODUCTION

Krukenberg tumours are a rare entity of secondary ovarian tumours. In 90% of cases, the primary origin is from gastrointestinal tract. The etiopathogenesis is still poorly elucidated¹. We report the unusual case of a sigmoid cancer manifested only by an ovarian metastasis.

PATIENT PRESENTATION

We report the case of a 45-year-old female patient who presented to our department with complaints of abdominal distension and abdominal pain, evolving in the context of deteriorating general condition and unexplained weight loss without associated digestive or urinary symptoms. The

patient had no personal or family history of colonic or gynaecological cancer

Clinical findings

On examination, she was found to be in poor general condition with a distended abdomen, palpable fixed abdominal-pelvic mass with a soft consistency without gaseous distension with some abdominal tenderness. On speculum examination, cervix appeared healthy and no contact bleeding. On vaginal examination there was a large fixed mass 3 finger-breadths (5-6cm) above the umbilical region. The rectal examination did not reveal any abnormality.

Diagnostic approach and therapeutic intervention:

The endovaginal ultrasound showed a giant solid cystic mass with a thickened wall and an anarchic Doppler image measuring 18x20x23 cm. The additional pelvic MRI showed a large abdominal pelvic solid-cystic mass measuring 20cm x 23cm x 29cm, with a small ascites (Figure 1). The abdominal-pelvic CT scan did not show any secondary locations.

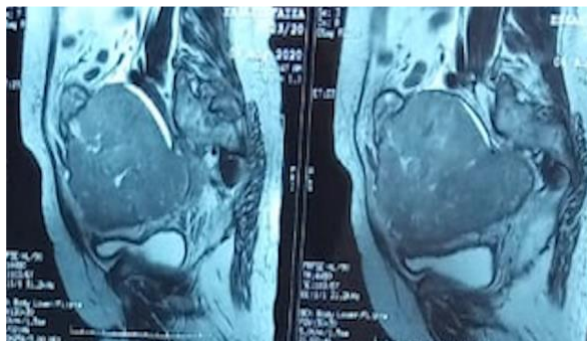


Figure 1: MRI of the abdomen and pelvis showing a large abdominopelvic mass at the superolateral aspect of the uterus measuring 20cm x 23cm x 29cm with a septate cystic mass arising from the ovary.

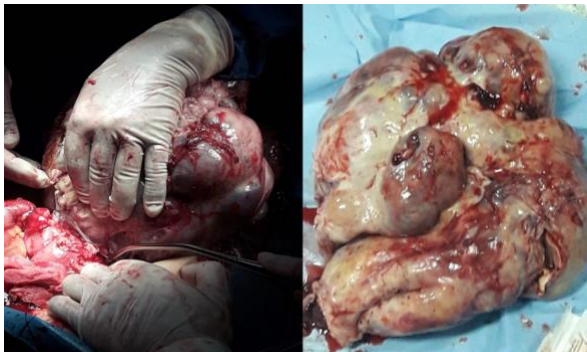

Figure 2: Image showing a left ovarian mass adherent to the sigmoid colon.

Therapeutic Intervention, Outcome and Follow-Up

The patient underwent exploratory laparotomy. Surgical exploration showed a small quantity of yellowish ascites. The presence of a left ovarian mass occupying the pelvis with a suspicious appearance of malignancy macroscopically and adherent to the sigmoid colon. (Figure 2). The uterus and right adnexa have no significant anomaly but there is presence of a stenosing sigmoidal tumour seen. There was the presence of 2 nodules of peritoneal carcinomatosis but no lesions seen on liver surface.

The decision was to perform a total hysterectomy and bilateral adnexectomy (total hysterectomy and bilateral salpingo-oophorectomy) and then perform a sigmoidal resection with terminal colostomy.

The histopathologic and immunohistochemical study was in favour of a moderately differentiated adenocarcinoma of the sigmoid colon and ovarian metastases of a moderately differentiated adenocarcinoma of colonic origin with peritoneal carcinomatosis. The patient benefited from 6 cycles of intravenous adjuvant chemotherapy with cisplatin and 5-FU, with a good clinico-radiological control after 16 months.

DISCUSSION

Krukenberg tumours are very rare, representing 2% of all ovarian tumours. It is usually unilateral or bilateral ovarian metastases with a mucinous component. The primary origin is gastrointestinal tract in 90% (70% of gastric origin, 14% of colonic origin).

Several questions are asked about this pathology, the main one being the mode of neoplastic dissemination. The proposed hypotheses of the mode of metastatic dissemination of these tumours which includes the hypothesis of transperitoneal dissemination is no longer retained because an injury on the serosa is obligatory whereas it is not seen in all cases². The increasing frequency of microscopic metastases located in the central part of the ovary, without concomitant capsular invasion, reinforces the theory of a possible hematogenous dissemination.

Other proposed hypotheses include retrograde lymphatic dissemination from the lumbo-aortic chain, immunotaxis, chemotaxis or hormonotaxis.

Usually, the age of onset is between 30 and 50 years (as in our index case 45 years) hence a high frequency in young women during the reproductive period. However, rare cases have been described in the literature in an older woman in 2002³ and in an adolescent girl.

Clinically, the signs of Krukenberg's tumours are frustrating and non-specific, such as abdominal distention from ascites or an abdominopelvic mass, vague digestive signs, etc. This explains the late diagnosis, which worsens the prognosis.

Most often, the diagnosis is made incidentally during a screening for a primary

cancer, most often gastrointestinal in origin or during surgery ⁴.

On imaging, ovarian metastases present as mainly tissue masses, multi-lobular solid-cystic with some well-defined intramural cystic images and signs of locoregional extension, peritoneal nodules. Imaging does not in any case allow differentiation between the primary and the secondary tumour but remains an essential tool in diagnostic work-up ⁵.

An ascitic aspiration with cytological and chemical analysis of the liquid allows in some cases the detection of malignant cells in a kittern ring.

Histological analysis is the only way to confirm the diagnosis. Ovarian involvement is most often bilateral (80%). Isolated right ovarian involvement is estimated to be between 9 and 28% and isolated left ovarian involvement varies between 40 and 50% of cases in the literature ⁶. These tumours have a benign macroscopic appearance with a smooth, bumpy or poly-lobed external surface, without adhesion or extension to neighbouring organs ⁷.

Microscopically, the presence of eccentrically nucleated "ring" epitheliomatous cells, either singly or in clusters, is characteristic of a Krukenberg tumour ⁸.

CA-125 is most often elevated and is used as a surveillance tool for early detection of ovarian metastases, as well as a prognostic marker. Studies have shown that survival is inversely proportional to the CA-125 level.

Treatment is initially surgical and consists of total hysterectomy with bilateral adnexectomy and omentectomy for the ovarian tumour. The primary gastrointestinal tumour would be treated according to its clinical stage of the tumour.

According to a meta-analysis by Ruggero Lionetti et al, cytoreductive surgery and in particular R0 cytoreductive surgery is the treatments that show evidence of improved overall survival. Regarding adjuvant chemotherapy, the results concerning its efficacy are contradictory but it seems that adjuvant chemotherapy cannot replace surgery in a satisfactory way.

On the other hand, hyperthermic intraperitoneal chemotherapy, although evaluated in few studies, appears not only effective alone or in combination with cytoreductive surgery, but also associated with fewer adverse effects than adjuvant chemotherapy. Neoadjuvant chemotherapy appears to be recommended only when attempting R0 surgery.

Finally, the combination of R0 surgery with hyperthermic intraperitoneal chemotherapy appears to be the most effective and safest treatment protocol. All published studies have shown that radiotherapy is totally ineffective ⁸.

The survival of patients with Krukenberg tumours is influenced by the primary tumour site. According to Wu et al ⁹, patients with tumour originating from the breast had the longest median overall survival of 31 months, followed by those with colorectal cancer with a median survival time of 21.5 months. The prognosis of patients with gastric origin was the lowest 11 months and this may be explained by the fact that prognosis of advanced gastric cancer is worse than that of advanced colorectal cancer. Ascites, young age, pregnancy, primary pelvic symptomatology are prognostic factors.

Krukenberg's tumors are rare and have a severe prognosis; the etiopathogenesis remains mysterious, thus limiting the diagnostic and therapeutic improvement. At present, the prognosis remains poor ⁸. The best-known prognostic factors are: late diagnosis, ovarian symptomatology, pleural and/or peritoneal effusion, young women during the genital period, non-aggressive treatment and poor timing of surgical procedures ⁸. Krukenberg tumors always constitute a real challenge for practitioners; hence the interest of a systematic gynecological examination in front of any digestive neoplasia along with the consideration of a radiological and digestive exploration in front of any ovarian tumor.

Screening recommendations still need to be developed in order to remedy the late diagnosis; Prophylactic oophorectomy remains a debated topic requiring more thought, although it seems to be at encourage in our socio-economic and health context.

CONCLUSION:

The Krukenberg neoplasms always represent a real challenge for the clinicians. Therefore, the need for a systematic gynecological examination before any conclusion on gastrointestinal neoplasia and conversely. Similarly, a radiological and endoscopic gastrointestinal tract exploration is also considered necessary before all ovarian tumours surgery.

The Patient's Point of View

The patient consented to the diagnostic approach and therapeutic management and she was satisfied with the initial results of the etiological assessment as well as the therapeutic results.

Informed Consent

The patient has given her free and informed consent for the writing and publication of this manuscript.

Conflicts of Interest

The authors declare no conflicts of interest.

Authors Contributions

All authors contributed to the writing and editing of the article. All authors have read and approved the finalized version of the manuscript.

REFERENCES:

1. Yakushiji M, Tazaki T, Nishimura H, Kato T. Krukenberg tumors of the ovary: a clinicopathologic analysis of 112 cases. *Nihon Sanka Fujinka Gakkai Zasshi*. 1987;39(3):479-85.
2. Savey L, Lasser P, Castaigne D. Mises au point tumeurs de Krukenberg. *JCHR*. 1996;133:9-10.
3. Praz, Nordback, Billing, Merlini. Krukenberg's tumor, three years after a colic carcinoma. *Swiss surgery*. 2002;8(5):237-9.
4. Jeung YJ, Ok HJ, Kim WG, Kim SH, Lee TH. Krukenberg tumors of gastric origin versus colorectal origin. *Obstetrics & Gynecology Science*. 2015;58(1):32-9.
5. Cho K, Gold B. Computed tomography of Krukenberg tumors. *American journal of roentgenology*. 1985;145(2):285-8.
6. El Mansouri A, Moumen M, Louahlia A, El Fares F. Tumeur de Krükenberg: un pronostic encore sombre: à propos de 4 observations. *Journal de gynécologie obstétrique et biologie de la reproduction*. 1993;22(5):497-500.
7. Seck A, Krami H, Meliani K, Marzouk N, El Farissi M, Benzoubeir N, et al. Les tumeurs de Krukenberg à propos de 7 observations. *Médecine du maghreb*. 2001;85:35-9.
8. Brahim EB, Chatti S, Ayachi M, Zidi Y, SalaH MB. Tumeur de krukenberg: etude anatomo-clinique de cinq cas. *Tunisie médicale*. 2007;85(9):806-10.
9. Wu F, Zhao X, Mi B, Feng L, Yuan N, Lei F, et al. Clinical characteristics and prognostic analysis of Krukenberg tumor. *Molecular and clinical oncology*. 2015;3(6):1323-8.