



Case Report

Hepatic Metastasis From Recurrent Ovarian Granulosa Cell Tumour: A Rare Entity

Shaliq Navas¹, Aanchal Bhayana², Neha Bagri^{3*}, Ritu Misra⁴

Department of Radio-diagnosis, VMMC & Safdarjung Hospital, New Delhi.
shaliqnavas@gmail.com¹, aanchalbhayana@gmail.com²,
drnehabagri@gmail.com³, misraritu@gmail.com⁴

ABSTRACT

Granulosa cell tumour (GCT) is a rare sex cord-stromal tumour of the ovary with a considerable propensity for late recurrences. However, liver metastasis is extremely rare, with an incidence of 5-6%. We present a case report of remote recurrence of GCT with liver metastasis in a patient with a past surgical history for right ovarian GCT many years back. GCT primarily has a low malignant potential, but it has a high tendency to recur with metastasis, usually within the pelvis. Inhibin B and AMH are the most accurate tumour markers for the detection of recurrent GCT. Ultrasound of the abdomen revealed a complex solid cystic mass in the retroperitoneum and multiple hepatic lesions, the biopsy from which revealed metastatic GCT. Henceforth, radiologists and gynaecologists need to be aware of delayed and remote recurrence of ovarian GCT with distant metastasis for appropriate management and follow-up of these patients.

*Correspondence:

Dr Neha Bagri
drnehabagri@gmail.com
Ph no. 9013606279

Keywords: Granulosa cell tumour, Ovary, Recurrence, Liver metastasis, Ultrasound

INTRODUCTION

Granulosa cell tumour (GCT) is a rare sex cord-stromal tumour of the ovary, which accounts for 2-5% of all ovarian tumours.¹ With a 25-30% incidence rate, GCT has a considerable propensity for late recurrences.² However, metastasis of the liver is extremely rare, with an incidence of 5-6%.¹ This rare case report describes a patient who underwent surgery for ovarian GCT eight years ago and then presented with retroperitoneal GCT and liver metastasis.

CASE REPORT

A 49-year-old female was admitted to the gynaecology department with pain in the abdomen associated with nausea. She had no complaints of weight loss, vaginal bleeding, or lower abdominal pain. A detailed history revealed a history of total abdominal hysterectomy with bilateral salpingo-oophorectomy done for the right ovarian granulosa cell tumour eight years back. Routine blood investigation (including CBC and LFT) and tumour markers AFP, CA19-9, CA 125, CA 15-3, estradiol and AMH were

within normal limits. However, the serum inhibin B value was elevated.

After these investigations, she was referred for an abdomen ultrasound, which revealed a large, predominantly solid mass measuring approximately 13.5x11.8x7.2 cm in size in the left anterior pararenal space. The mass showed a mild increase in vascularity. The left kidney was displaced posteriorly, and the mass extended to the aortic bifurcation inferiorly. There was no vascular or bowel invasion. There were three similar morphology, predominantly solid masses with interspersed cystic areas in segments 2, 5 and 8 of the liver, the largest measuring 7.1x3.9x2.7 cm. cm cm in size.

the abdominal organs were normal. Subsequently, a CECT abdomen was performed, which confirmed the ultrasound findings and helped better delineate the fat planes and extent of the retroperitoneal mass. The hepatic lesions showed moderate progressive enhancement without any wash-out in the delayed phase.

The patient underwent an ultrasound-guided biopsy of the most extensive hepatic lesion, which revealed a metastatic granulosa cell tumour. The nuclei of the tumour cells were grooved, giving the appearance of the classical coffee bean, the characteristic features of GCT. The Call Exner bodies were seen within the microfollicular pattern of this tumour. On histo-

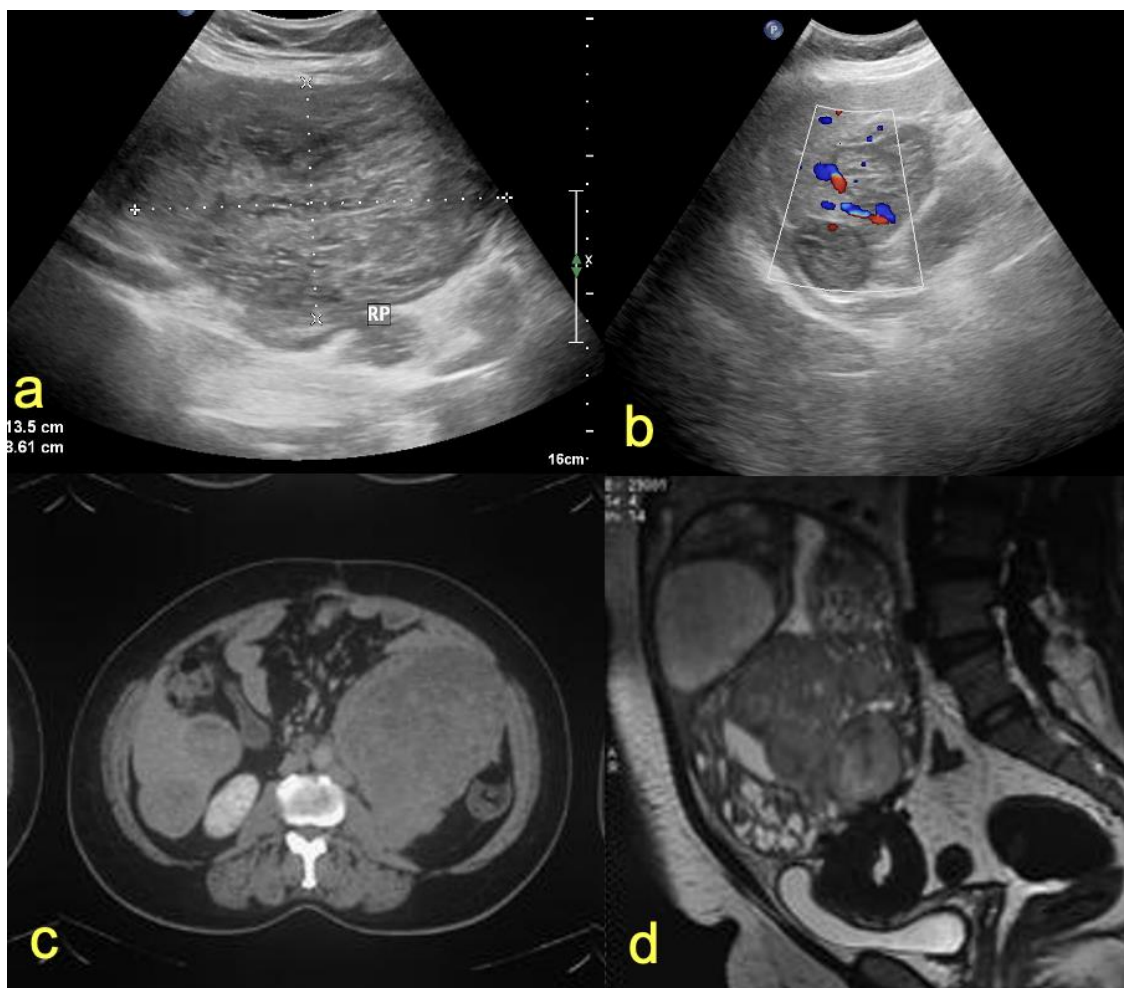


Figure 1a-b. US abdomen shows retroperitoneal and hepatic masses. 1c. CECT abdomen shows a mass in the left anterior pararenal space and multiple hepatic masses. 1d. Previous pelvic MRI (8 years back) showed similar morphology right ovarian mass.

There was no apparent residual /recurrent mass in the pelvic region. The rest of

chemistry, the tumour was positive for inhibin, vimentin, calretinin, S-100, ER, PR and focally

positive for SMA. Considering the advanced and metastatic stage of the disease, the patient was a non-surgical candidate, and chemotherapy was started and kept on follow-up.

DISCUSSION

Granulosa cell tumour (GCT) is a type of ovarian sex cord-stromal tumour which accounts for 2-5% of all ovarian cancers. There are two types of GCT- adult type (90%) and juvenile type (5%).¹ In the adult type of GCT, patients usually present with post-menopausal bleeding due to the prolonged exposure of the endometrium to the tumour-derived estradiol. Abdominal pain is another joint presentation, as the tumour is generally large and haemorrhagic. GCT usually has a low malignant potential but a high tendency to recur, and metastasis is typically present within the pelvis. Distant metastasis is very rare. Liver metastasis accounts for no more than 5-6% of cases.² Inhibin B and AMH are the most accurate tumour markers for the detection of recurrent GCT.³

The imaging reveals predominantly solid or complex solid-cystic mass, commonly arising from the ovary, which can be confirmed on cross-sectional imaging. Hepatic metastatic lesions also show similar morphology on imaging. They might closely resemble a primary HCC, cystadenoma, complicated hepatic cysts, or other liver metastases.⁴ Hence, histopathology is needed for a definite diagnosis of this entity.

In the present case, the retroperitoneal recurrence of ovarian GCT, along with hepatic metastasis, makes it an infrequent presentation and a key learning point for radiologists and surgeons. Past surgical history and knowledge of previous histopathology reports played a crucial role. Primary retroperitoneal GCT are again very rare masses, and very few have been reported in the existing literature. GCTs are known to be aggressive in case of recurrence, as seen in the present case. This case highlights the importance

of long-term follow-up of ovarian GCT because more than 50% of recurrence occurs after five years.

CONCLUSION

In this case, the retroperitoneal recurrence of ovarian GCT and hepatic metastasis emphasises the gravity of long-term follow-up. Inhibin B and AMH are the most accurate tumour markers for recurrent detection. The key message is that remote recurrence with hepatic metastasis can be a rare, aggressive presentation of ovarian GCT that has been treated long ago. Hence, radiologists and surgeons must know this entity and follow up on these patients.

Acknowledgement: Thankful to all the contributors

Conflicts of interest: None

Source(s) of support: Nil

Contributor's detail: All authors contributed equally to this work

REFERENCES

- Schumer ST, Cannistra SA. Granulosa cell tumor of the ovary. *J Clin Oncol.* 2003 Mar 15;21(6):1180-9. doi: 10.1200/JCO.2003.10.019. PMID: 12637488.
- Yu S, Zhou X, Hou B, Tang B, Hu J, He S. Metastasis of the liver with a granulosa cell tumor of the ovary: A case report. *Oncol Lett* 9: 816-818, 2015.
- Aleter A, Mahajan PS, Petkar MA, Abdulmajeed HA, Khalaf H, Elmoghazy W, Elaffandi A. Late Cystic Metastasis of an Ovarian Granulosa Cell Tumor to the Liver. *Cureus.* 2021 Sep 17;13(9): e18051.
- Neste MG, Francis IR, Bude OR. Hepatic metastasis from granulosa cell tumor of the ovary: CT and sonographic findings. *AJR* 1996; 166:1122-24.